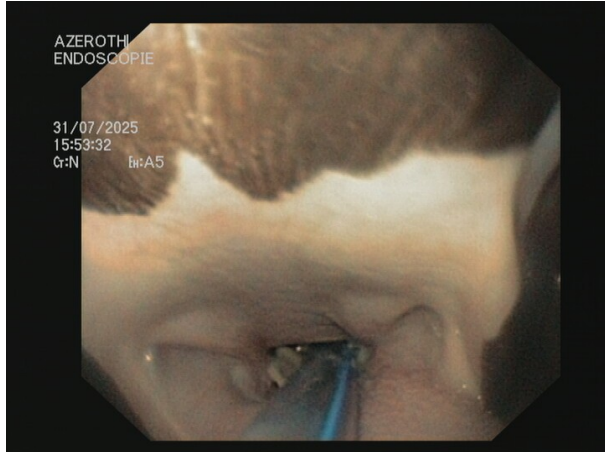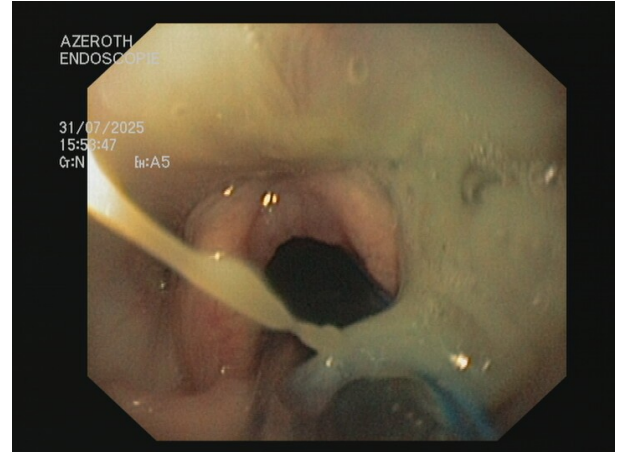
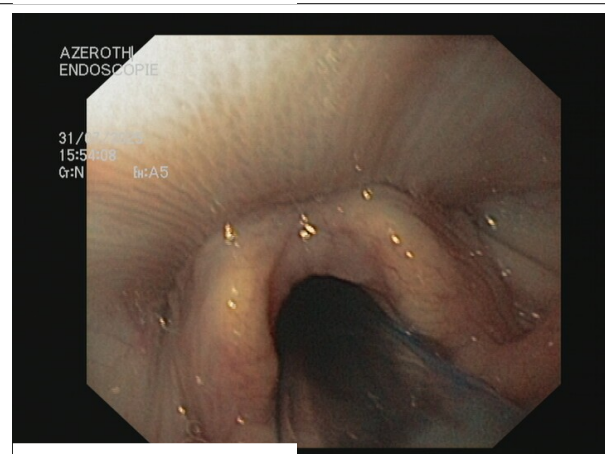


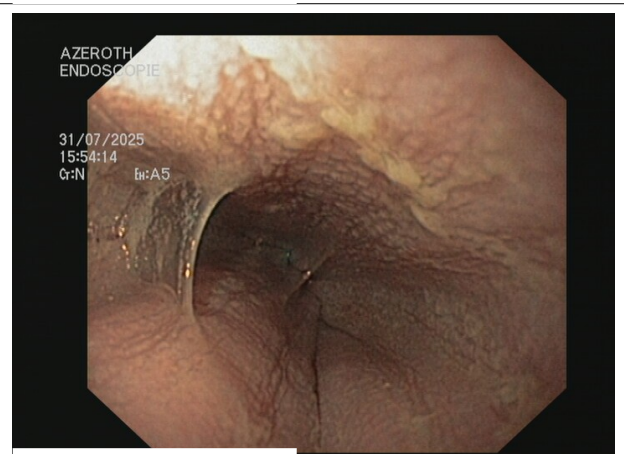
Cavité buccale



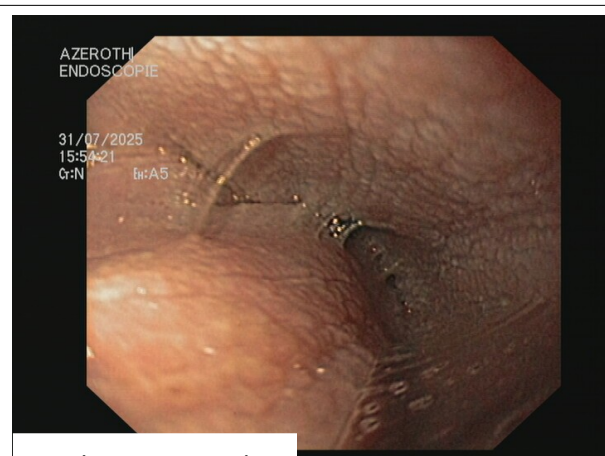Larynx



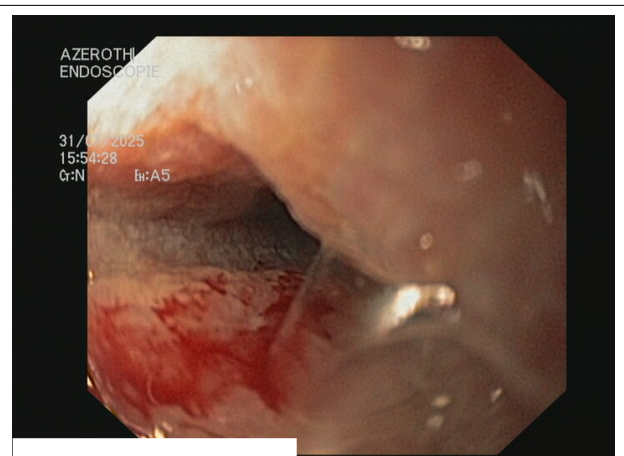
Larynx



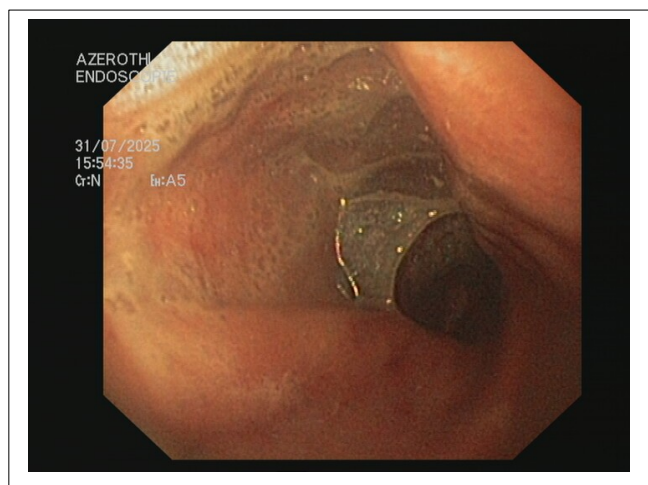Œsophage proximal



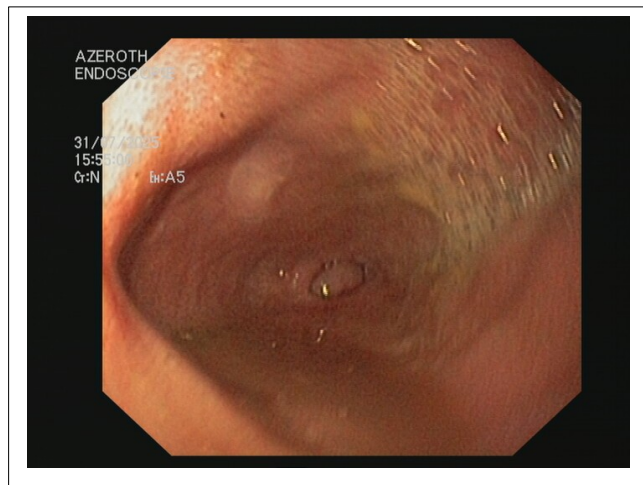
Œsophage proximal



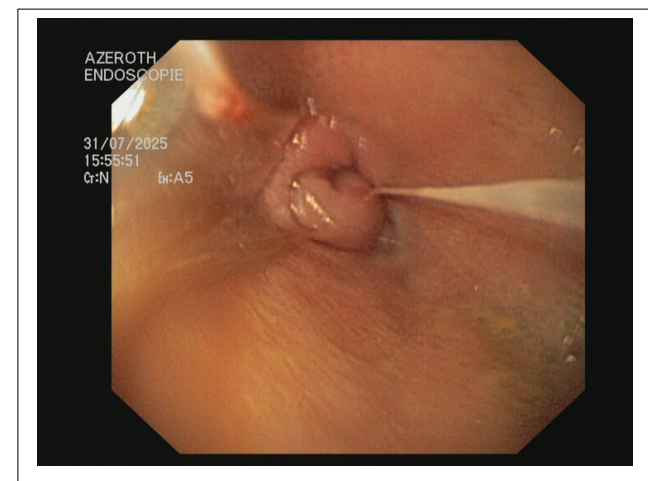
Œsophage moyen



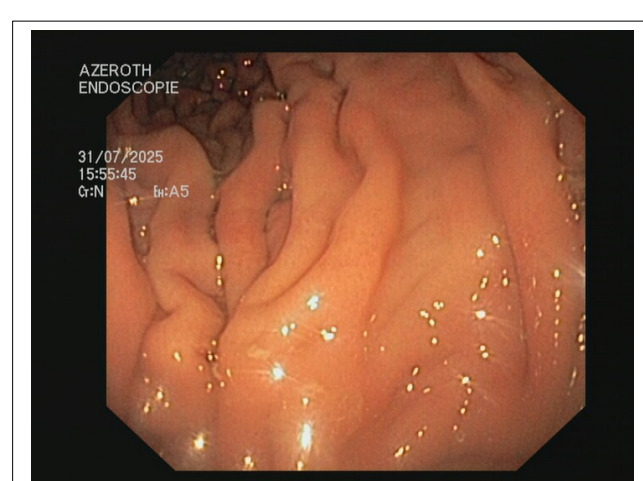
Œsophage moyen



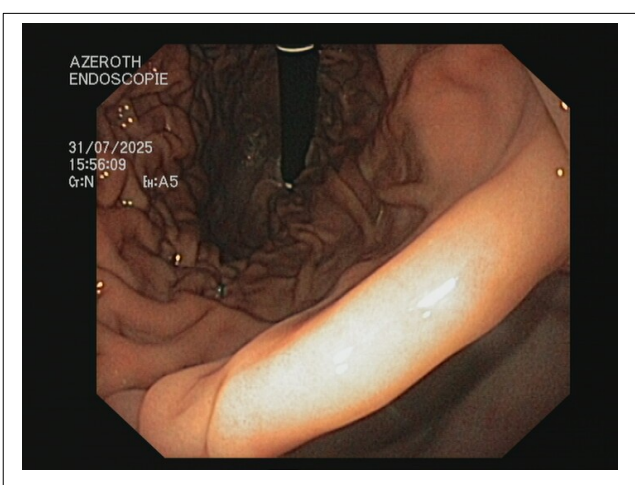
Œsophage distal



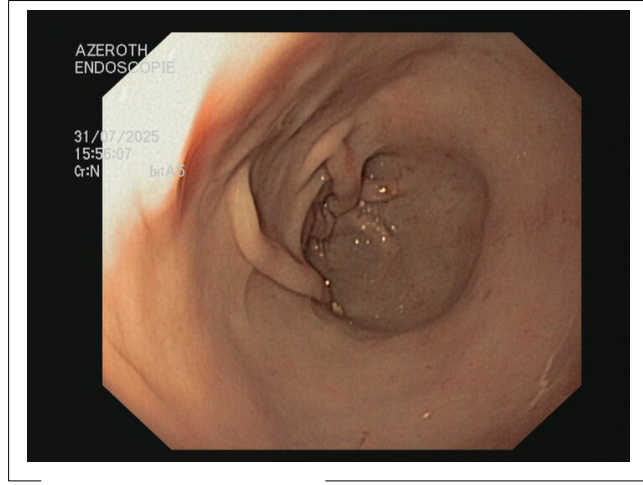
Cardia



Corps de l'estomac



Rétrovision estomac



Pylore